



Is frozen section routinely necessary in patients with well-localized solitary parathyroid adenoma?

Oktay Irkorucu^{1*}

Abstract

Introduction: Solitary adenoma is the cause of primary hyperparathyroidism in 85% of cases.

Objectives: In this study, we aimed to evaluate the routine necessity of frozen section (FS) in patients with well-localized solitary parathyroid adenoma in the absence of intraoperative parathyroid hormone (IOPTH) measurement and gamma probe usage.

Patients and Methods: Forty-four patients had tissue samples submitted for intraoperative FS consultation. Two surgeons' opinion on the excised tissue were recorded independently and compared with the histopathology reports.

Results: In the postoperative 24 hour blood calcium and PTH levels in patients with SPA were found to be significantly lower when compared with preoperative levels ($P=0.001$). All patients had samples sent for intra-operative FS where 100% of samples were found to be parathyroid tissue.

Conclusion: Parathyroid adenoma excision can be safely and successfully performed without the need for FS examination in patients with well localized solitary adenomas. Although our study is encouraging, further studies are still needed on this subject.

Keywords: Parathyroid, Frozen, Adenoma

Please cite this paper as: Irkorucu O. Is frozen section routinely necessary in patients with well-localized solitary parathyroid adenoma? J Parathyroid Dis. 2016;4(2):36-39.

Copyright © 2016 The Author(s); Published by Nickan Research Institute. This is an open-access article distributed under the terms of the Creative Commons Attribution License, which permits unrestricted use, distribution, and reproduction in any medium, provided the original work is properly cited.

Introduction

Today, the treatment of primary hyperparathyroidism (pHPT) is mainly surgical and pHPT is the result of a single adenoma in 85% of patients (1-6). Historically, until the 1990s, for localization of all four parathyroid glands, bilateral cervical exploration had been the standard surgical treatment for pHPT. In the past two decades however, significant improvements in localization techniques have facilitated further advances in surgical management. Today, minimally invasive parathyroidectomy is one of the most preferred technique among endocrine surgeons (3-6).

Many adjunct methods such as intraoperative parathyroid hormone (IOPTH) measurement, gamma probe usage, and frozen section (FS) examination recommended to find and excise abnormal parathyroid(s) (7-14). FS is one of the most popular method and routinely used by many surgeons (6-16). On the other hand, FS is an unreliable technique for distinguishing adenomas from multiglandular disease (12). An adenoma can be diagnosed with confidence if only one gland of the four glands is enlarged. In FS evaluation, the pathologist does not make a diagnostic definition of the disease. In fact, FS is generally used for distinguishing the parathyroid tissue from non-parathyroid tissue, not to diagnose parathyroid adenoma (12-20). Nevertheless, the use of FS to distinguish parathyroid tissue from non-parathyroid tissue has an ac-

curacy of 99.2% (3). An experienced endocrine surgeon, during daily practice, distinguishes parathyroid tissues and protects them in every thyroid operation. From this stand point; we asked the question; Is FS really necessary for a well-localized solitary parathyroid adenoma?

Objectives

In this study, we decided to evaluate the necessity of FS in patients with well-localized solitary parathyroid adenoma in the absence of IOPTH monitoring and gamma probe usage.

Materials and Methods

Study design

Forty-four patients with pHPT operated on by a single surgeon were included in this study. Only the patients who had SPA with preoperative concordant imaging studies included in the study. Concordance was accepted as positive when both the side and site (upper or lower) were matched. The patients who have recurrent and permanent hyperparathyroidism were excluded from the study. The diagnosis of pHPT was mainly based on symptoms, hypercalcemia and an elevated serum PTH level. Surgeries performed according to the criteria determined by the last NIH consensus panel (11). Localization of the pathological gland(s) was made in all patients preoperatively by both US and MIBI imaging of the neck. The diagno-

Received: 8 February 2016, Accepted: 4 April 2016, ePublished: 18 April 2016

¹Sağlık Bilimleri University, Adana Health Research and Training Center, General Surgery Department, Adana, Turkey

*Corresponding author: Oktay Irkorucu; Email: oktaytip@yahoo.com

■ Implication for health policy/practice/research/medical education

In a study on 44 patients, we found that frozen section is not routinely necessary in patients with well-localized solitary parathyroid adenoma

sis of pHPT was confirmed by an endocrinologist in all patients. All operations were performed under general anaesthesia without using IOPTH monitoring or gamma probe. Patients were discharged after the serum calcium and PTH samples were collected at the postoperative 24th hour. The outpatient consultation was arranged at postoperative month 1.

Surgical procedure

In this study, there were 2 surgical options for patients: first was image guided, minimally invasive surgery and the second was bilateral neck exploration. Bilateral neck exploration was performed only in patients who had concordant thyroid and parathyroid pathology. No conversation to bilateral neck exploration was needed in patients with minimally invasive surgery. All 44 patients had tissue submitted for intra-operative FS consultation. Two surgeons' (primer surgeon and assisting surgeon) opinion on excised the tissue were recorded independently so as to avoid bias and FS performed for definitive tissue identification. FS was performed by embedding the tissue freezing (Bioblock, Atom Scientific Ltd) compound which then was rapidly frozen. Sections 6 mm were cut, fixed in 95% alcohol for 40 seconds and thereafter stained with hematoxylin and eosin stains. Demographic features, preoperative diagnostic methods, type of surgical treatment, postoperative period and final pathological examination were also recorded.

Ethical issues

The research followed the principles of the Declaration of Helsinki. Informed consents was obtained and the research was agreed by the Ethics Committee of the Adana Numune Research and Training hospital.

Statistical analysis

Data were evaluated by using SPSS 20.0 for Windows. Con-

tinuous data were shown as mean \pm standard deviation (SD) or median (minimum-maximum). Kruskal-Wallis test, Mann-Whitney-U test and Wilcoxon test were used to compare the parameters in groups. Statistical significance was defined as a *P* value $<$ 0.05.

Results

Forty-four (mean age 54 + 13 years, m/f = 3/41) patients with solitary parathyroid adenoma underwent to parathyroid surgery. Twenty-four of them underwent minimally invasive surgery whereas other patients underwent bilaterally neck exploration. Of those with thyroid pathology, 14 cases had nodules in both lobes, whereas 4 cases had nodules only in the left lobe and 2 cases only in the right lobe.

Biochemical tests

In the post-operative 24-hour serum calcium, phosphate, and PTH levels in patients with SPA were found to be significantly lower when compared with preoperative levels. The median preoperative blood calcium, and PTH level was 11.4 mg/dl, and 202.0 pg/ml, respectively. In the post-operative 24 hours, the median postoperative blood calcium, and PTH levels were 8.8 mg/dl, and 20.9 pg/ml, respectively (*P* = 0.0001). Table 1 shows the preoperative and postoperative measurements of serum calcium, phosphate and PTH. Normocalcemia was achieved in 100% of patients. These patients were followed up for 6 months and the calcium levels did not show any increase.

Anatomical distribution of adenomas

Forty-one of 44 (93.18%) adenomas were found to be in the lower pole positions. Twenty-five of 44 adenomas were right-sided (56.81%) whereas 19 of all adenomas were left-sided lesions (43.19%). Only 3 of 44 adenomas were in the upper poles (right/left = 1/2).

Postoperative complications

In this study, only two patients had postoperative hypocalcemia and required intravenous calcium treatment. There was no reported voice disorder, and no other major complications such as major vessel injury and hematoma.

Table 1. Comparison of preoperative and postoperative biochemical parameters

Parameter	n	Mean	Median	SD	Preop-Postop1		Preop-Postop2	
					z	P ^a	z	P
Preop Ca	44	11.8	11.4	1.1				
Postop Ca 1	44	8.8	8.8	0.7	-5.7	0.0001	-5.8	0.0001
Postop Ca 2	44	8.9	9.0	0.7				
Preop P	44	2.7	2.7	0.8				
Postop P 1	44	3.0	3.0	0.5	-2.8	0.005	-4.5	0.0001
Postop P 2	44	3.4	3.2	0.6				
Preop PTH	44	408.5	202.0	553.7				
Postop PTH 1	44	69.5	20.9	272.8	-5.8	0.0001	-5.8	0.0001
Postop PTH 2	44	97.6	43.3	242.7				

Abbreviations: PTH, parathyroid hormone; Ca, calcium; P, phosphate; n, number of patients; Postop 1, value in the postoperative 24 hour; Postop 2, value at the postoperative first month.

^a Wilcoxon test, *P* $<$ 0.05 is considered as statistically significant.

Postoperative follow-up

All patients had tissue samples sent for intra-operative FS examination where 100% of samples were found to be parathyroid tissue. All cases of patients were followed up within 6 months. In 44 (100%) patients, US and MIBIS correctly identified the adenoma later found on surgery and all of the patients recovered well. The final pathology reports in all cases were parathyroid adenoma and the agreement between the surgeon and the histopathological analysis was 100%.

Discussion

Today, pHPT is the result of a single adenoma in 85% of patients (3-19). In patients with SPA, the resolution of metabolic disturbances and clinical symptoms necessitates the surgical removal of adenoma(s) (12-18). It is important to confirm that the resected tissue is indeed parathyroid adenoma. FS has long been used for this purpose. Although FS cannot distinguish between parathyroid adenoma and parathyroid hyperplasia, FS can reliably answer the question is the resected tissue parathyroid or not? (12,13). On the other hand, the answer does not warrant the success of the operation. In fact, what is the need of the surgeon during surgery for correct diagnosis and effective operation should be asked. In a study conducted by Suliburk et al (18) they reported that their failure rate was (2.2%) and the main reason for failure was double adenomas (59%). Additionally in another study, Carter et al (19) reviewed 137 cases of hyperparathyroidism followed for 6-72 months to determine the reasons for failure. In their study, reasons for failure were a missed gland in 62% of cases, an ectopic gland in 15% of cases, supernumerary glands in 15% of cases. From this stand point, we can speculate that, the major reason of failed surgeries are preoperatively failing in the diagnosis of a second adenoma not inappropriate distinguishing of parathyroid and non-parathyroid tissues (3,19,20). In our study, the success rate of surgery was 100% and it was similar to literature. In the postoperative 24 hour, serum calcium and PTH levels in patients with SPA were found to be significantly lower when compared with preoperative levels ($P=0.001$). Normocalcemia was achieved in all cases. The higher success rate of our study may be attributable to our preoperative strict work up. In this study all patients had concordant imaging studies. Concordance was accepted as positive when both the side and site (upper or lower) were agreed. Second reason may be due to the experience of the primary surgeon. All operations performed in our study by an experienced surgeon. In this study, the FS performed in all cases and all of them are reported as parathyroid tissue. Additionally the surgeons opinion were similar to the FS results in all cases (100%). In 44 cases, final histopathological diagnosis were parathyroid adenoma. The major reason for these results may be due to the clear visual characteristics of a parathyroid adenoma. It is easy for an experienced surgeon to distinguish glistening, encapsulated, and lobulated gross appearance of a parathyroid adenoma from a non-parathyroid tissue (Figures 1 and 2).

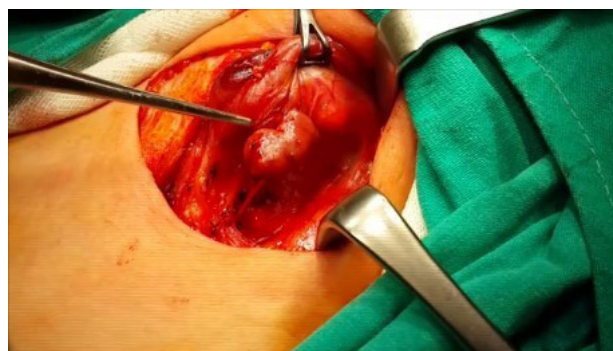

Figure 1. The glistening, encapsulated, and lobulated gross appearance of a solitary parathyroid adenoma during classical bilaterally neck exploration.

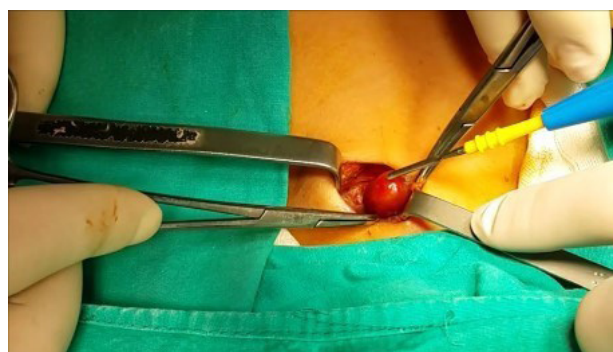


Figure 2. Gross appearance of a easily recognized solitary parathyroid adenoma during minimally invasive surgery.

Although the FS is widely used to identify tissue type during parathyroid surgery in patients with hyperparathyroidism, questions regarding its accuracy have been raised (12). FS error in identifying tissue character has been attributed as more important factor contributing to failed parathyroid surgery, and some have called for the abolition of the routine standard FS during parathyroid exploration, citing an error rate of 10% (12-14). In their study, Roslyn et al (16) reported that parathyroid tissue is easily mistaken for lymphoid tissue and thyroid tissue during FS evaluation and is caused to surgical failure in 55% of patients with recurrent hyperparathyroidism. Additionally, Levin and Clark (17) identified FS error as one of the six most relevant factors contributing to recurrent or persistent pHPT. Every technique has limitations and FS is not an exception. Parathyroid identification by FS is subject to many well recognized technical problems commonly encountered during tissue freezing (15). Some authors recommended using IOPTH monitoring, gamma probe and ex-vivo parathyroid needle aspiration in order to use FS (13-20). However, some authors have announced that IOPTH monitoring is useless if pathologic parathyroids are successfully localized (9,10). Callender and Udelsman (13) reported that, an alternative that is less costly is ex vivo aspiration of resected parathyroid tissue with accompanying measurement of the PTH level in the aspirate. If the aspirate is off-scale ($PTH >1000$ pg/mL), then the resected tissue is not thyroid or lymph node, and there is no need to obtain a FS (13). Additionally, Dewan

et al (20) reported that, experienced parathyroid surgeons need not routinely request FS examination. In our study, none of the adjunct techniques used. There was not a doubt for surgeon to distinguish the parathyroid tissue and non-parathyroid tissue. In this study, most of the adenomas were found in the lower pole and the surgeon was very familiar with this anatomic field. Additionally, the patients in our study were a specific group of patients with a well-localized solitary parathyroid adenoma.

Although, the main goal of the present study was not a cost analysis. Omitting to perform an intraoperative consultation with FS may decrease the cost. On the other hand, potential cost of repeat imaging studies and surgery may increase the total cost and should be borne in mind. The object of this study was an analysis of a single experienced surgeon's ability to correctly identify parathyroid tissue on gross examination in a selected group. According to our results, parathyroid adenoma excision can be safely and satisfactorily performed without the requirement for intra-operative FS examination in patients with well localized solitary adenomas. These finding should not be generalized to mean that FS is neither useful nor necessary in parathyroid surgery. FS should be used in the cases of the inexperienced surgeon, multiple gland disease, ectopic glands, reoperant necks, and otherwise technically difficult primary surgeries.

Conclusion

The surgeon's decision to omit FS examination, especially when guided by preoperative concordant MIBIS and US should be balanced against the potential risk for reoperation. Although our study encouraging, further researches are still needed to detect the useless of routine usage of FS in patients with well-localized SPA.

Limitations of the study

Our study has some limitations. This study was conducted on a selected group of patients who are residents in Mediterranean region of Turkey. Additionally, the patients were operated by a single surgeon in a single institute.

Author's contribution

OI was the single author of the manuscript.

Conflicts of interest

The author declare no conflict of interests.

Ethical considerations

Ethical issues (including plagiarism, data fabrication, double publication) have been completely observed by the author.

Funding/Support

None.

References

1. Yeo H, Uranga P, Roman S. Conventional Surgical Management of Primary Hyperparathyroidism. In: Oertli D, Udelsman R, eds. *Surgery of the Thyroid and Parathyroid Glands*. Berlin Heidelberg: Springer-Verlag; 2007:260-9.
2. Al-lami A, Riffat F, Alamgir F, Dwivedi R, Berman L, Fish B, et al. Utility of an intraoperative ultrasound in lateral approach mini-parathyroidectomy with discordant pre-operative imaging. *Eur Arch Otorhinolaryngol*. 2013;270:1903-08.
3. Noureldine SI, Gooi Z, Tufano RP. Minimally invasive parathyroid surgery. *Gland Surg*. 2015;4:410-41.
4. Kelly CW, Eng CY, Quraishi MS. Open mini-incision parathyroidectomy for solitary parathyroid adenoma. *Eur Arch Otorhinolaryngol*. 2014;271:555-60.
5. Leupe PK, Delaere PR, Vander Poorten VL, Debruyne F. Pre-operative imaging in primary hyperparathyroidism with ultrasonography and sestamibi scintigraphy. *B-ENT*. 2011;7:173-80.
6. Gracie D, Hussain SSM. Use of minimally invasive parathyroidectomy techniques in sporadic primary hyperparathyroidism: systematic review. *J Laryngol Otol*. 2012;26:221-7.
7. Vandebulcke O, Delaere P, Vander Poorten V, Debruyne F. Incidence of multiglandular disease in sporadic primary hyperparathyroidism. *B-ENT*. 2014;10:1-6.
8. Chen H, Mack E, Starling JR. A comprehensive evaluation of perioperative adjuncts during minimally invasive parathyroidectomy: which is most reliable? *Ann Surg*. 2005;242:375-80.
9. Ikeda Y, Takayama J, Takami H. Minimally invasive radioguided parathyroidectomy for hyperparathyroidism. *Ann Nucl Med*. 2010;24:233-40.
10. Mihai R, Palazzo FF, Gleeson FV, Sadler GP. Minimally invasive parathyroidectomy without intraoperative parathyroid hormone monitoring in patients with primary hyperparathyroidism. *Br J Surg*. 2007;94:42-47.
11. Bilezikian JP, Brandi ML, Eastell R, Silverberg SJ, Udelsman R, Marcocci C, et al. Guidelines for the management of asymptomatic primary hyperparathyroidism: summary statement from the Fourth International Workshop. *J Clin Endocrinol Metab*. 2014;99:3561-9.
12. Westra WH, Pritchett DD, Udelsman R. Intraoperative confirmation of parathyroid tissue during parathyroid exploration: a retrospective evaluation of the frozen section. *Am J Surg Pathol*. 1998;22:538-44.
13. Callender GG, Udelsman R. Surgery for Primary Hyperparathyroidism. *Cancer*. 2014;1:3602-16.
14. Prey M, Vitale T, Martin S. Guidelines for practical utilization of intraoperative frozen sections. *Arch Surg*. 1989;124:331-5.
15. Silva EG, Kraemer BB. Parathyroid glands. In: Silva EG, Kraemer BB, eds. *Intraoperative pathologic diagnosis: frozen section and other techniques*. Baltimore: Williams and Wilkins; 1985:253-264.
16. Roslyn JJ, Mulder DG, Gordon HE. Persistent and recurrent hyperparathyroidism. *Am J Surg*. 1981;142:21-25.
17. Levin KE, Clark OH. The reasons for failure in parathyroid operations. *Arch Surg*. 1989;124:911-914.
18. Suliburk JW, Sywak MS, Sidhu SB, Delbridge LW. 1000 minimally invasive parathyroidectomies without intraoperative parathyroid hormone measurement: lessons learned. *ANZ J Surg*. 2011;81:362-5.
19. Carter WB, Carter DL, Cohn HE. Cause and current management of reoperative hyperparathyroidism. *Am Surg*. 1993;59:120-4.
20. Dewan AK, Kapadia SB, Hollenbeak CS, Stack BC Jr. Is routine frozen section necessary for parathyroid surgery? *Otolaryngol Head Neck Surg*. 2005;133:857-62.